

Canine pheochromocytoma

Isabelle Desmas, Davies Veterinary Specialists, Manor Farm Business Park, UK, examines the diagnosis and the administering of medical treatment prior to surgical treatment of canine pheochromocytoma

Pheochromocytoma is an uncommon malignant catecholamine-producing tumour that arises from chromaffin cells in the adrenal medulla. Its diagnosis, formerly considered challenging, is a much easier task today, thanks to normetanephrine assay on blood and/or urine. Treatment is primarily surgical. A medical treatment should be implemented prior to surgery or when surgery is not an option, to decrease the potentially life-threatening symptoms associated with excessive secretion of catecholamines.

KEY POINTS

- Pheochromocytoma is a neoplasia derived from chromaffin cells in the adrenal medulla. It secretes excessive amounts of catecholamines (adrenaline and noradrenaline);
- Pheochromocytoma is a tumour of the older dog;
- Staging is recommended, in order to evaluate local infiltration of the tumour as well as potential metastatic spread;
- Urine or plasma normetanephrine assay are diagnostic tools for pheochromocytoma;
- Surgical resection of pheochromocytoma is associated with a low mortality rate of 6-15% if the surgery is not an emergency procedure and when it follows a medical treatment;
- Medical treatment with α -antagonist may help to control hypertension secondary to excessive catecholamine release.

ADRENAL GLANDS

ANATOMY AND FUNCTION

There are two adrenal glands in the body which are divided in two main portions: cortex and medulla. The cortex produces steroid hormones and is made of three

different layers which each synthesises different products: *zona glomerulosa* (mineralocorticoids/aldosterone), *zona fasciculata* (glucocorticoids/cortisol), and *zona reticularis* (sexual hormones), see Figure 1. The medulla secretes catecholamines (adrenaline, noradrenaline). The substances are released following a physiological stress (hypotension, fear/stress, hypoglycaemia for instance).

TUMOUR OF THE ADRENAL GLANDS

Adrenal tumours represent 1-2% of canine neoplasias. They can be benign or malignant and may arise from the cortex or the medulla. In any of these locations, tumours can be functionally active or not. When they are functional, adrenal tumours secrete excessive amounts of the substances they would normally release physiologically at a low rate. Rarely, adrenal tumours can represent metastatic disease. In dogs, there is no side or layers that shows a higher prevalence of neoplastic change.

Neoplastic proliferations of adrenal cortex are classified as adrenal adenoma or carcinoma, depending on their biological behaviour. Adrenal medullary tumours are called pheochromocytomas.

CLINICAL SIGNS

Clinical signs are vague and intermittent (see below). They are due to excessive release of catecholamines and subsequent hyperstimulation of adrenergic receptors α and β , as well as to local infiltration of the tumour into the adjacent tissues and vessels.

Clinical signs include:

- Collapse, lethargy;
- Hypertension which may translate into epistaxis, acute blindness secondary to retinal detachment, acute kidney injury, etc.);

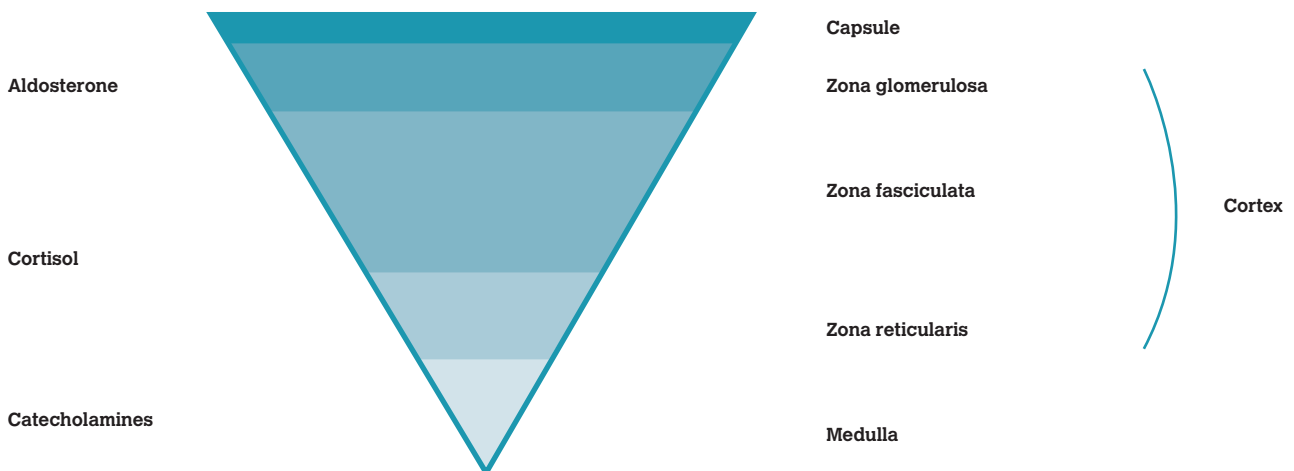


Figure 1: Anatomy of the adrenal gland (schematic drawing of a transverse section) and its products.

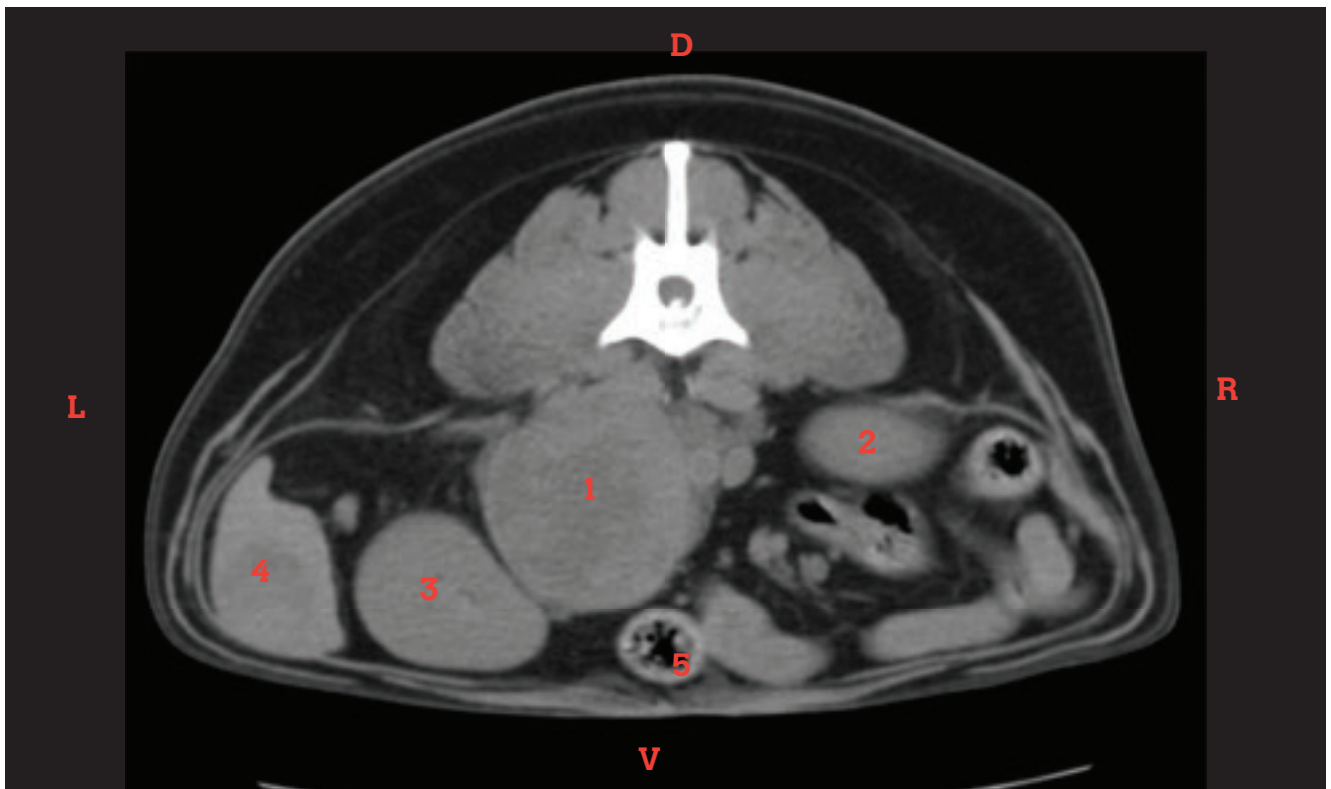


Figure 2: 6x6x9.5cm left adrenal mass in a medium-size crossbreed dog. 1.Pheochromocytoma/adrenal mass 2. right kidney, 3. left kidney, 4. spleen, 5. gastrointestinal tract

- Tachyarrhythmias;
- Tachypnoea;
- Polyuria and polydipsia (PUPD);
- Anorexia, weight loss (chronic disease);
- Ascites secondary to venous thrombus; and/or
- Vomiting, diarrhoea.

DIAGNOSTIC APPROACH

Adrenal masses in dogs are often incidental findings. More than 50% of canine pheochromocytomas are identified during investigation of a concurrent comorbidity or during necropsy examination. The diagnosis should be a step-by-step approach:

- Abdominal images to define the degree of local infiltration;
- Tests to determine if the adrenal mass is functional and if it arises from the cortex or medulla; and
- Staging with thoracic and abdominal imaging to look for metastatic spread to distant sites or a primary tumour elsewhere that could have metastasised to the adrenal.

IMAGING MODALITIES

1. RADIOGRAPHS

Although quite a low sensitive method, an abdominal radiograph may help to identify an adrenal mass. Nearly half of adrenal carcinomas and adenomas are mineralised, but only 10% of pheochromocytomas are reported to have mineralisation.

2.ABDOMINAL ULTRASOUND

Abdominal ultrasound may help to visualise the adrenal mass

and help to define its infiltration into adjacent tissues (organs or vessels). Furthermore, staging of the rest of the abdomen can be performed on the same occasion and ultrasound-guided biopsies can be carried out if indicated.

3. COMPUTED TOMOGRAPHY SCAN OR MAGNETIC RESONANCE IMAGING

Abdominal computed tomography (CT) scan or magnetic resonance imaging (MRI) are the most sensitive methods to visualise adrenal masses (see Figure 2). A study reports that performing a CT scan prior to surgery may help in the detection of vascular invasion with a sensitivity of 92% and a specificity of 89-100%. These imaging modalities prove to be very useful tools to plan a surgery and define better the prognosis. A contrast product, metaiodobenzylguanidine (MIBG), is sometimes used in human medicine to detect pheochromocytomas as its molecular structure is similar to noradrenaline and it would be stocked in similar locations in the body. This detection method is not used in current veterinary practice but has been reported.

Thoracic staging may prove to be useful as the pulmonary metastatic rate is around 10%. Thoracic radiographs or CT scan may also indicate cardiomegaly and/or pulmonary congestion secondary to chronic hypertension.

DIAGNOSIS

Baseline blood tests and urinalysis are recommended to search for concurrent comorbidities and as a preanesthetic requirement. Pheochromocytoma on its own should not trigger any changes on the blood work. However, urine specific gravity may be inadequate secondary to PUPD.

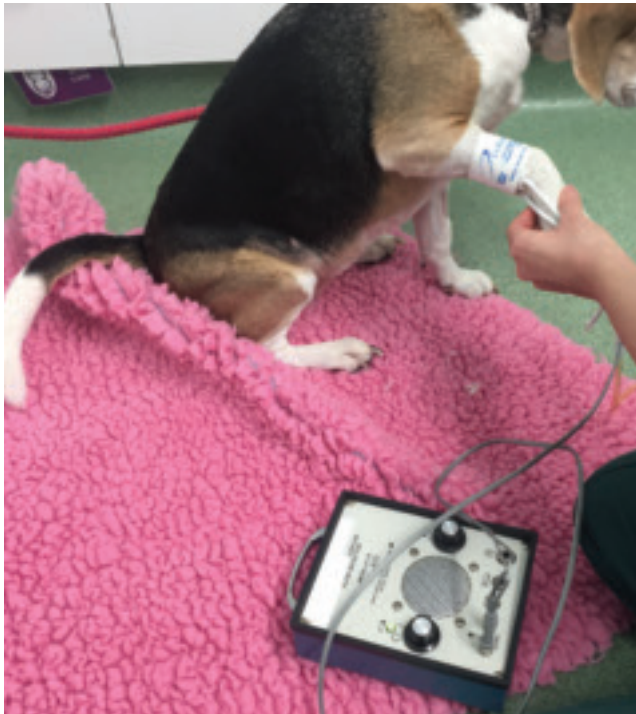

Figure 3: Non-invasive blood pressure with Doppler machine.

Blood tests may also help in ruling in or out a functional tumour of the adrenal cortex (hyperadrenocorticism). It is important to note that the suspicion or confirmation of hyperadrenocorticism does not rule out the presence of a concomitant pheochromocytoma. A functional cortical adrenal tumour should be confirmed with a low dose dexamethasone suppression test.

Non-invasive blood pressure (see Figure 3) should be performed as a priority test. Repeated measurements should be carried out because catecholamine peaks are often intermittent and hypertension may be missed on a single measurement. Eye fundus should also be performed to look for retinal bleeding.

SPECIFIC DIAGNOSTIC TESTS

Final diagnosis of pheochromocytoma can be carried out by performing assays of the secretion products of the tumour. Cytological diagnosis of neuroendocrine tumours is additionally difficult to perform and is likely to give less information compared to the functional tests. In the past, assaying the catecholamines metabolites in the blood was supposed to be useless due to the intermittent nature of their secretion. They therefore, used to be measured in the urine which gives a more accurate picture of the circulating blood products over 24 hours.

In dogs, collection of the urine over 24 hours is not practical. Urinary normetanephrine: creatinine ratio and plasma normetanephrine assay can reflect secretion products over a period of time and have been proven to be useful in the diagnosis of canine pheochromocytoma. They are additionally easy tests to perform. Sensitivity of 100% and specificity of 97.6% have been reported for plasma-free normetanephrine concentration assay for the diagnosis of canine pheochromocytoma.

HISTOPATHOLOGY

The origin of an adrenal tumour (ie. cortex versus medulla) can be determined on cytology alone. However, cytology is not a reliable tool in distinguishing benign from malignant neuroendocrine neoplasia. Furthermore, potential severe and even fatal side effects could arise in the event of a catecholamine-producing tumour being sampled, such as pain, haemorrhage, and severe hypertensive crisis due to sudden release of catecholamine. Special stain (chromogranin A and synaptophysin) may help further in the diagnosis of pheochromocytoma when the histopathology is not definitive.

TREATMENT

MEDICAL

Owners should be instructed to surround their pets with a stress-free environment and avoid intense exercise to minimise catecholamine release. It is also important to treat any comorbidities so that the patient is stable for further surgical procedure.

Medical treatment for pheochromocytomas should be started at least two weeks before a surgical procedure or when surgery is not an option. It consists in the administration of phenoxybenzamine, which is a β -adrenergic antagonist that irreversibly binds to both β -1 and β -2 adrenergic receptors and blocks the α -adrenergic response to circulating catecholamines. Treatment with phenoxybenzamine prior to removal of pheochromocytomas has been proven to lower mortality rates during surgery. The recommended dose for phenoxybenzamine is 0.2-1.5mg/kg BID. You must be particularly careful about consequent hypotensive episodes, while the tumour is not active, as the hypertension peaks are often intermittent. Propranolol (β -blocker, 0.15-1mg/kg TID) can be used to manage tachycardia and arrhythmia but it should never be used without phenoxybenzamine in pheochromocytoma cases. Radiation therapy and/or chemotherapy have not yet been reported to be effective in dogs but anecdotal evidence of their benefit is reported in humane medicine.

SURGICAL

Adrenalectomy is the treatment of choice. Anaesthesia and surgery should be carefully planned. Blood type should be performed prior to surgery in case a transfusion is required. Ideally a central catheter or arterial catheter should be in place for blood pressure measurements. Electrocardiogram should also be recorded continuously. The surgeon should communicate with the anaesthetist in charge of the case when the pheochromocytoma is manipulated so that appropriate measures are taken rapidly in case of severe catecholamine release. A rapid-acting β -blocker called phentolamine, can be administered intravenously during surgery as required.

Surgical approach can be challenging but the size of the tumour, as well as invasion into the adjacent vessels, do not preclude surgical removal. Vascular dissection is necessary for removal of intact tumour thrombus alongside the neoplastic gland. When surgery is not performed as an

emergency procedure and/or when patients have received pretreatment with phenoxybenzamine, mortality rates of 6-13% have been reported. Surgery may even be curative if complete resection is achieved and in the absence of metastatic disease.

Positive prognostic factors reported for canine pheochromocytomas prognostic factors are:

- Complete resection;
- Absence of metastatic disease;
- Size of the tumour (<3cm);
- Absence of comorbidities;
- Pretreatment with phenoxybenzamine; and
- No or limited invasion into adjacent organs.

CONCLUSION

Pheochromocytomas are rare tumours that carry a challenging diagnosis. However, assay of their secretion products (normetanephrine assay in the urine and/or plasma) have made the diagnosis much more approachable recently. The treatment of choice is surgical and it should be preceded by a medical treatment with phenoxybenzamine (β -blocker). Phenoxybenzamine can also be administered when surgery is no longer an option.

READING LIST

Barthez PY, Marks SL, Woo J et al. Pheochromocytoma in dogs: 61 cases (1984-1995). *J Vet Intern Med* 1997; 11(5): 272-278

Bommarito DA, Lattimer JC, Selting KA et al. Treatment of a malignant pheochromocytoma in a dog using 131I metaiodobenzylguanidine. *J Am Anim Hosp Assoc* 2011; 47(6): e188-94

Gostelow R, Bridger N, Syme H. Plasma-free metanephrine

and free normetanephrine measurement for the diagnosis of pheochromocytoma in dogs. *J Vet Intern Med* 2013; 27: 83-90

Herrera MA, Mehl ML, Kass PH et al. Predictive factors and the effect of phenoxybenzamine on outcome in dogs undergoing adrenalectomy for pheochromocytoma. *J Vet Intern Med* 2008; 22: 1333-1339

Lang JM, Schertel E, Kennedy S et al. Elective and emergency surgical management of adrenal gland tumors: 60 Cases (1999-2006). *J Am Anim Hosp Assoc* 2011; 47: 428-435

Masari F, Nicolli S, Romanelli G et al. Adrenalectomy in dogs with adrenal gland tumors: 52 cases (2002-2008). *J Am Vet Med Assoc* 2011; 239(2): 216-21

Quante S, Boretti FS, Kook PH et al. Urinary catecholamine and metanephrine to creatinine ratios in dogs with hyperadrenocorticism or pheochromocytoma, and in healthy dogs. *J Vet Intern Med* 2010; 24: 1093-1097

Schultz RM, Wisner ER, Johnson EG, Macleod JS. Contrast-enhanced computed tomography as a preoperative indicator of vascular invasion from adrenal masses in dogs. *Veterinary Radiology & Ultrasound* 2009; 50(6): 625-629

Bertazzolo W, Didier M, Gelain ME et al. Accuracy of cytology in distinguishing adrenocortical tumors from pheochromocytoma in companion animals. *Vet Clin Pathol* 2014; 43(3): 453-459

Gregori T, Mantis P, Benigni L et al. Comparison of computed tomographic and pathologic findings in 17 dogs with primary adrenal neoplasia. *Vet Radiol Ultrasound* 2015; 56(2): 153-159

Salesov E, Boretti FS, Sieber-Ruckstuhl NS et al. Urinary and plasma catecholamines and metanephrines in dogs with pheochromocytoma, hypercortisolism, nonadrenal disease and in healthy dogs. *J Vet Intern Med* 2015; 29: 597-60

READER QUESTIONS AND ANSWERS

1. WHICH OF THE FOLLOWING PRODUCTS DO PHEOCHROMOCYTOMAS SECRETE IN EXCESS?

- A aldosterone
- B cortisol
- C sex hormones
- D catecholamines

2. WHICH OF THE FOLLOWING DIAGNOSTIC TEST(S) SHOULD BE USED TO DIAGNOSE CANINE PHEOCHROMOCYTOMA?

- A Cytology from ultrasound-guided fine needle aspirates
- B Urinary normetanephrine: creatinine ratio
- C Continuous arterial blood pressure measurements
- D Plasma normetanephrine assay

3. WHICH OF THE FOLLOWING DRUG SHOULD BE ADMINISTERED ORALLY PRIOR TO SURGICAL REMOVAL OF PHEOCHROMOCYTOMA?

- A Propranolol

- B Enalapril
- C Phenoxybenzamine
- D Amlodipine

4. WHICH OF THE FOLLOWING HAS NOT BEEN PROVEN TO BE PROGNOSTIC FACTOR FOR CANINE PHEOCHROMOCYTOMA?

- A Size of the tumour
- B Completeness of resection
- C Number of weeks of pretreatment with β -blocker medication
- D Presence of metastatic disease

5. WHAT IS THE TREATMENT OF CHOICE FOR PHEOCHROMOCYTOMAS?

- A Adrenalectomy
- B Oral phenoxybenzamine
- C Chemotherapy with doxorubicin
- D Curative-intent radiation therapy

ANSWERS 1: D; 2: B AND D; 3: C; 4: C; 5: A